

Hihi (Stitchbird) Breeding on Tiritiri Matangi Island

2015 – 2016 Breeding Season

Mhairi McCready¹ & John G. Ewen^{1, 2}

- 1) Institute of Zoology, Zoological Society of London, Regents Park, NW1 4RY, London, United Kingdom.
2) Contact email: john.ewen@ioz.ac.uk



Suggested citation:

McCready M. and Ewen J.G. 2015. *Hihi (Stitchbird) Breeding on Tiritiri Matangi Island: 2015-2016 Breeding Season*. Internal Report. Department of Conservation, New Zealand.

Note: There is a data embargo in place so please contact John Ewen prior to using data reported.

1. Summary

1.1 Key results for the current year

This season has seen a further decline in the numbers of hihi on Tiritiri with the pre-breeding census providing numbers as low as those in 2004. Productivity however was higher than the previous season and numbers of fledglings produced per female was the highest for the last 5 years. On the contrary to this the percentage hatching success was at an all-time low.

129 and 141 individuals were recorded in the September 2015 and February 2016 censuses respectively. The first egg was laid on 20th September 2015 and the last chick fledged on 15th March 2016, this was a long and extended breeding season.

Table 1 Number of females breeding in the population on Tiritiri Matangi

	First year females	Older females
Seen in September survey	9	29
Breeding this season	13	40
Fledglings produced	18	112

1.2 Pit-tagging

The application of pit tags has continued this year; they are embedded in plastic colour bands which are slightly longer than those traditionally used. These bands act as unique identifiers for their bearers, which can be read wirelessly by a data logger mounted, for example, on a feeder. This technology would allow for richer and more accurate population data, amongst other possibilities.

All but two of the adult male population have been tagged as have all of the juveniles from this season. All of the tags have been applied in the above metal position. There have been slippages over the metal and in two cases down onto the foot. These slippages were from tags that have not been welded and work continues to catch all birds and weld their pit tags and colour bands. There may be an option to move to a smaller pit tag size to further reduce the risk of slippages.

2. Introduction

2.1 Background

The hihi, or stitchbird (*Notiomystis cincta*), is an endemic forest-dwelling passerine that was once found throughout the north island. The species declined rapidly in the late 1800s due to a loss of habitat, introduced predators, and possibly disease. The only remaining naturally occurring population is on little barrier island. In addition, there are five translocated populations maintained on Tiritiri Matangi Island, Kapiti Island, Karori sanctuary in Wellington, Maungatautari near Hamilton, and Bushy Park near Whanganui.

Hihi are sexually dimorphic, territorial cavity nesters with a mating system characterized by extra-pair and forced copulations. They breed between September and March, averaging two clutches of 4-5 eggs each. Hihi forage for nectar, fruit and insects and translocated populations rely heavily on provisioned sugar water in times of scarcity.

2.2 Site description

Tiritiri Matangi is a 220 hectare island roughly 3 kilometres long and one kilometre wide. It is located in the Hauraki Gulf, 28 kilometres north of downtown Auckland. Extensively farmed in the 1900's, Tiri has been replanted with over 280,000 trees since 1984 in an attempt to recreate the original northern broadleaf coastal forest.

The remnant mature forest on Tiritiri Matangi is dominated by kohekohe, taraire and pohutakawa. Other species on the island include: taupata, karamu, hangehange, mahoe, mapou, whau, ngaio, puriri, totara, rewarewa, hoheria, hinau, pigeonwood, kowhai, karo, akeake, manuka, kanuka, kawakawa, five finger, houpara, wharangi, rangiora, cottonwood, mingimingi, taurepo, native broom, koromiko, kumarahou, astelia, flax, muehlenbeckia, native jasmine, supplejack, and tree ferns.

Tiritiri Matangi is free from introduced predators, although there are several pairs of morepork (*Ninox novaeseelandiae*) and they are known to eat hihi. Two species of honeyeater, tui (*Prosthemadera novaeseelandiae*) and bellbird (*Anthornis melanura*), occur naturally on Tiri and compete with the hihi for food. Aggressive bellbirds regularly displace hihi at the sugar feeders. Tui, however, are excluded from the feeder cages by virtue of their larger size.

2.3 Personnel

The 2015-16 breeding season on Tiritiri Island was managed and monitored by Mhairi McCready. Victoria Franks was continuing her PhD fieldwork and was here throughout the breeding season.

Volunteers this season were: Christine Friis, Kate Lee, Keryn McCracken and Emilie Vergauwe. Volunteer help is always useful and appreciated. All volunteers were competent in the tasks set for them. These volunteers were organised by Mhairi McCready and Dave Jenkins (island ranger), as the normal route through DOC was not working. Unfortunately this meant the volunteers arrived late in the season after the busiest breeding time where they could have been a greater help and had a more complete experience.

3. Methods

3.1 Surveys

A pre-breeding survey and a post-breeding survey were conducted at the end of September 2015 and February 2016. Each of these involved approximately 40 person-hours spent recording band combinations of birds found throughout bush patches and at sugar feeders. A less-experienced volunteer was enlisted for the February survey. A trial of recording birds using their pit tags, antenna and data loggers situated at sugar feeders was carried out alongside the February survey.

3.2 Distribution and placement of nest boxes

All major bush patches on the island contain hihi nesting boxes. No new boxes were installed this season, there are 190 boxes currently spread across the island, which is more than enough boxes available for the population.

3.3 Nest site monitoring

Completed nests were checked almost daily until eggs were laid. When eggs were found to be warm or the female observed sitting for more than 10 minutes on 2 consecutive days incubation was confirmed. These nests were not checked again until day 13 of incubation, after which they were checked every day to check for hatching and until the chicks were 10 days old. After day 10 the nests were checked every-other day until day 21 when the chicks were banded. After banding the nests were not checked again until day 29 and everyday thereafter to determine fledging dates.

3.4 Nest box maintenance

Thirty three nest boxes were replaced with new one as they had been out in the bush for six years. All other nest boxes were cleaned at the beginning of the season. During the season all boxes that had been used for a breeding attempt were brought back to base and scrubbed with water, sprayed with trigene and left to dry in the sun for 24 hours before being returned. The backboards were scrubbed and sprayed with trigene at the time of box removal so they could dry before the box was returned.

3.5 Supplementary feeding regime

Sugar water was provided *ad libitum* in chicken-feeder-style plastic feeders placed in feeding stations at 5-6 locations on the island. Feeders were cleaned in hot soapy water, rinsed, and then sprayed with trigene, allowing a minimum of 5 minutes contact time. These were then rinsed and left to dry. Feeding stations were cleaned and disinfected with trigene on Mondays, Wednesdays and Fridays.

3.6 Banding and measurements

Nestlings were banded, weighed, measured and had blood drawn at 21 days old, on a few occasions day 22 or 23. Tarsus measurements were "to the notch" and "full length"; "head- to-bill" was measured from back of the head to the tip of the beak. Each nestling was given a c-size metal band, a grey pit tag and a combination of 2 plastic colour bands. All plastic bands were sealed using the new welding method. For a list of band combinations and measurements please contact John Ewen (john.ewen@ioz.ac.uk).

3.7 Health

Mite control was carried out this year. Nestlings with mites were treated with frontline twice. Before nest boxes were replaced with new boxes (as detailed in 3.4) and nests replaced with a fake nest made from wire mesh and polar fleece following the SOP. Only two nests required total replacement suggesting the mite infestations this season were low. Four birds (2 male, 2 female) were found dead this season and one male found sick which later died in captivity, necropsy reports are found in the appendix.

4. Results

Visitor numbers to Tiritiri Matangi have been estimated using the number of passengers travelling on the ferry, this was 30,525 for 2015.

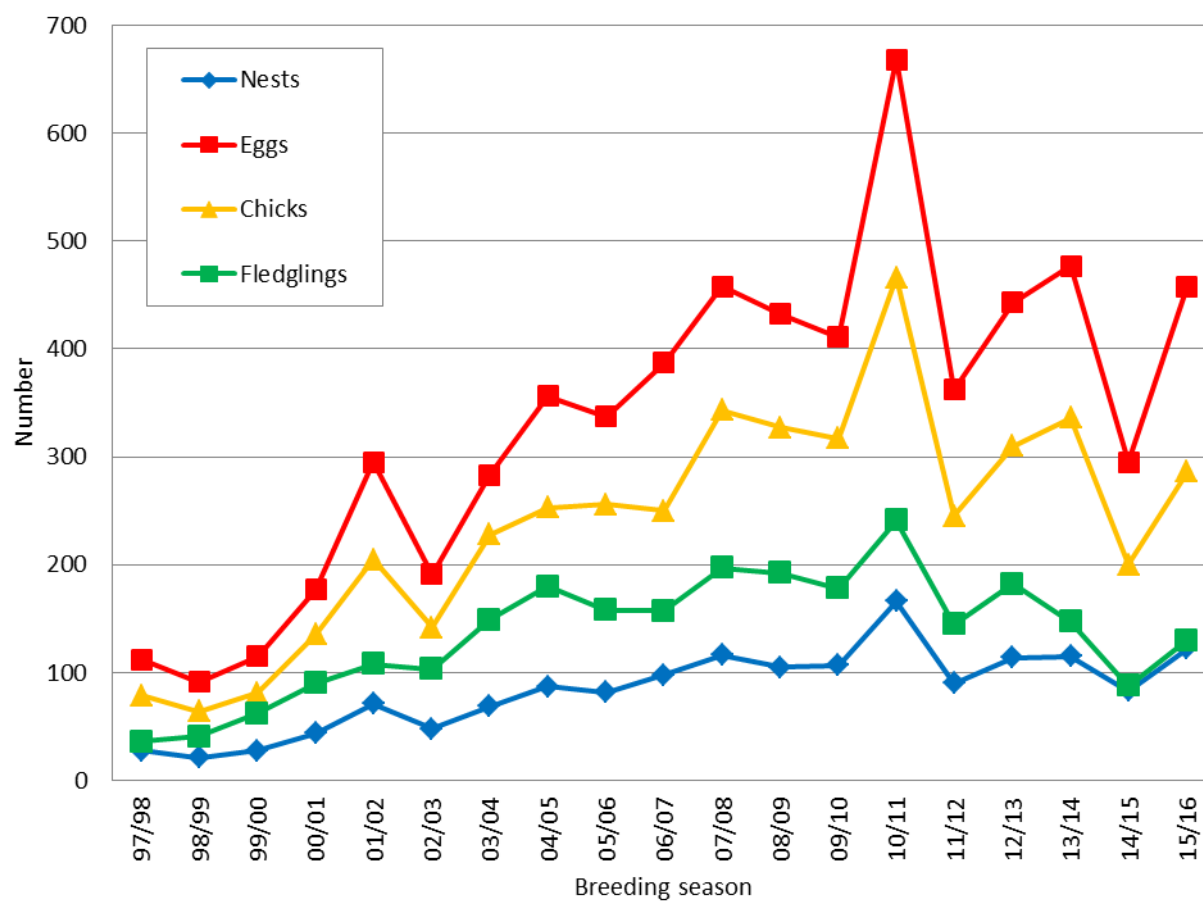


Figure 1 Number of nests, eggs, chicks and fledglings produced on Tiritiri Matangi from 1997 to 2015

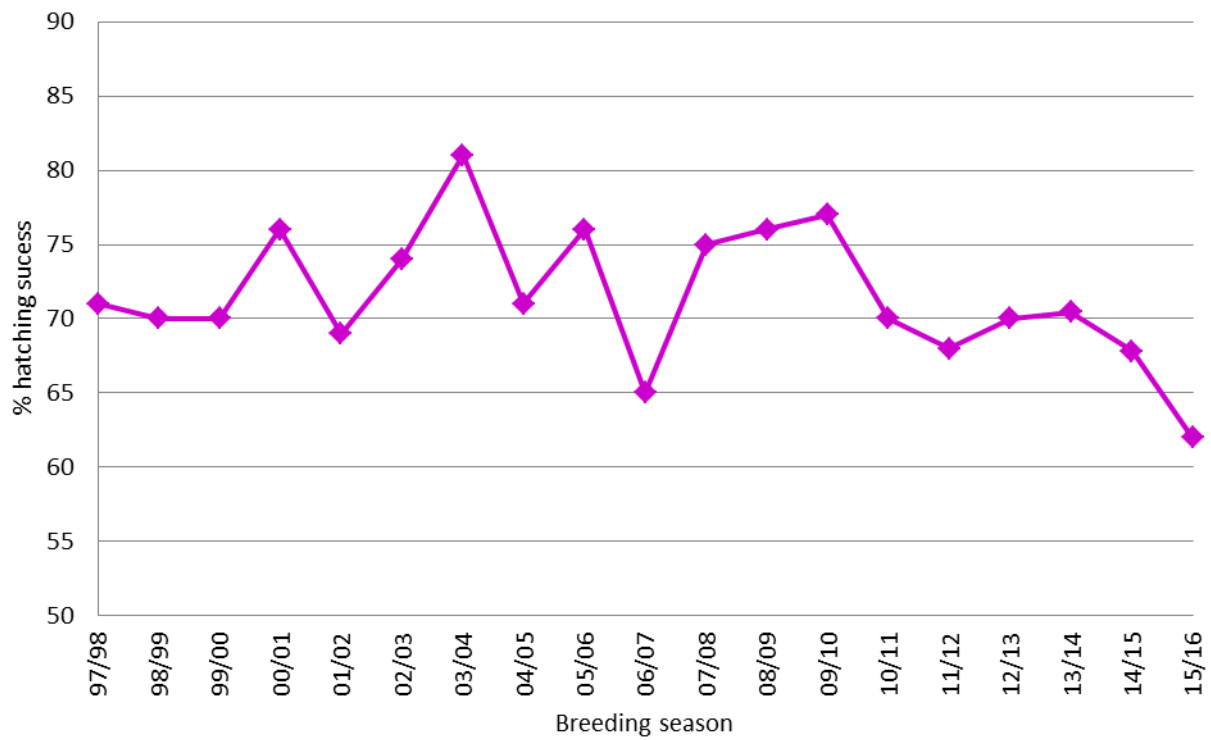


Figure 2 Hatching success on Tiritiri Matangi from 1997 to 2015

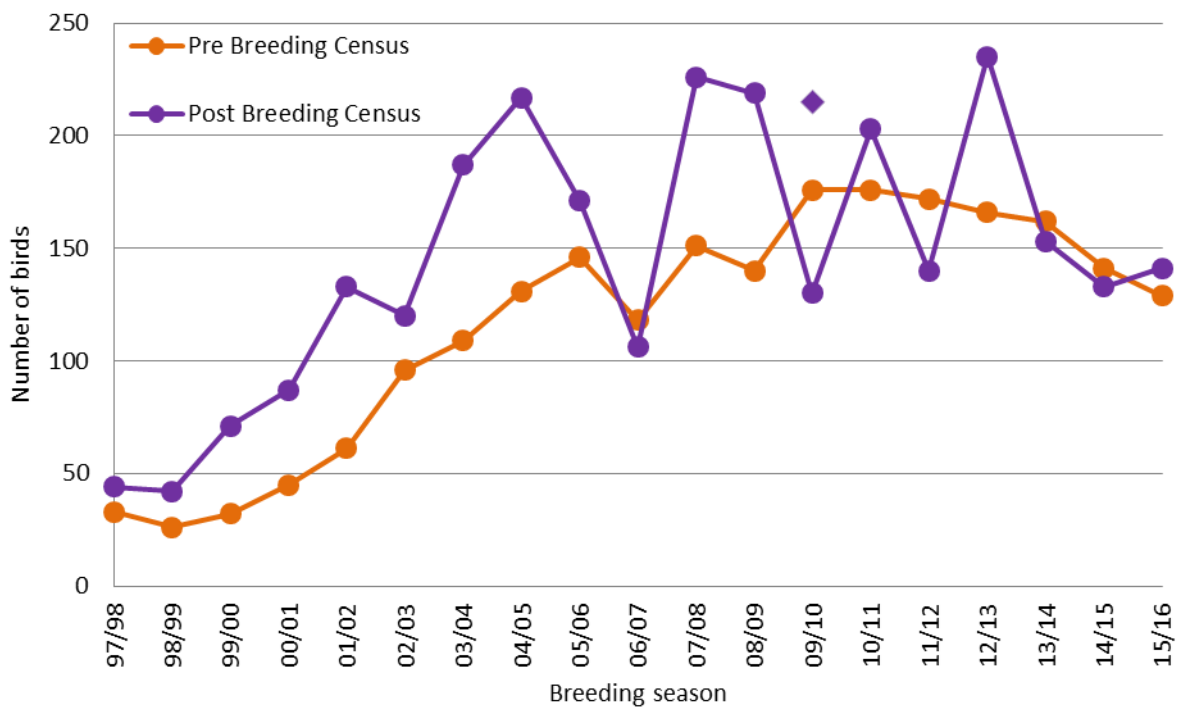


Figure 3 Number of birds recorded each year on Tiritiri Matangi during the two annual surveys from 1997 to 2016. Note that the survey of 09/10 took place immediately after juveniles were translocated; the single diamond shows the survey result including those removed.

The results of the trial survey method using data loggers and antenna on the feeder cages were: 48 individuals recorded, 10 of these were not sighted by observers and 1 male had not been seen all season.

5. Colour band loss

The loss of one or more colour bands from an individual hihi results in an incomplete colour combination, making identification during population surveys and breeding monitoring ambiguous. This problem has increased in recent years to the point that 26% of birds recorded in the September 2014 survey were missing one or more rings. During the 2014-15 season efforts were made to reduce this problem and bands were fixed with superglue.

During the September 2015 survey 19% of birds were noted as missing one or more bands, unfortunately this is likely to mean that the superglue fixing was unsuccessful as a long term solution. It was decided this season to trial heat sealing the joint of the plastic band. A battery powered soldering iron was used to melt the plastic and form a welded join. All juveniles from this season and 36% of the adult population have had their colour bands welded and so far there have been no joint failures or loss of bands. The type of plastic the bands are made from has an effect on the ease of melting, the acetal bands are easiest to melt and form the best join.

6. Acknowledgments

The Department of Conservation and the Supporters of Tiritiri Matangi (SoTM) are critical components of this project. Many thanks to Dave Jenkins, the ever-supportive Tiri ranger. So many SoTM members were helpful, enthusiastic and interested as always and we appreciate their commitment to the hihi and this island project. Hihi conservation also benefits hugely from the Hihi sponsors, Wesfarmers Industrial and NZ Safety Ltd.

7. Appendix (necropsy reports)

Institute of Veterinary, Animal and Biomedical Sciences

PATHOLOGY REPORT

Submitter's Ref.: C-79306	Date Sent: 11/11/2015	Accession No.: 52733
---------------------------	-----------------------	----------------------

TO: Mhairi McCready
Department of Conservation
Tiritiri Matangi Island

Species: Avian-WL (1)	Sex: Male	Age: 9 Years	Breed: Hihi (Stitchbird)
ID: C-79306	At Risk: 150	Affected: 1	Dead: 1
Owner: Department of Conservation	Prev. Accn.:	Type: Post Mortem	

HISTORY

Found dead Saturday 8/11/2015. Mhairi McCready performed necropsy and tissues submitted fixed in formalin.

GROSS FINDINGS

Notes on dissection:

- exterior of body looked fine, some blood coming out of beak
- blood also found in throat once opened
- muscle cover good, not skinny
- hard mass found attached to liver, has been sent in a sample pot
- possible plaques on lung, whitish green patches

HISTOPATHOLOGY

Liver: the majority of hepatocytes contain moderate amounts of granular, golden-brown pigment, likely haemosiderin and/or lipofuscin.

Kidney: small numbers of proximal tubular epithelial cells contain small amounts of pigment resembling haemosiderin.

Mass: the mass is composed of amorphous eosinophilic material containing multiple small colonies of coccoid bacteria; the mass is partially bordered by a thin layer of multinucleated giant cells and epithelioid macrophages.

Sections of heart, lung, intestine and brain show no obvious abnormalities.

DIAGNOSIS

Mass next to liver: bacterial granuloma

Likely Aspergillosis

COMMENTS

The mass described next to the liver is composed of bacterial and inflammatory debris. The green plaques you describe on the lung sound suspicious for the fungal infection, Aspergillosis. Both the bacterial and fungal infections are likely opportunistic infections and this bird will have been no risk to in-contact birds.

Institute of Veterinary, Animal and Biomedical Sciences

PATHOLOGY REPORT

Submitter's Ref.:	Date Sent: 18/12/2015	Accession No.: 52822
-------------------	-----------------------	-----------------------------

TO: Mhairi McCready
Department of Conservation
Tiritiri Matangi Island
Auckland

Species: Avian-WL (1)	Sex: Female	Age: Adult	Breed: Hihi (Stitchbird)
ID: None	At Risk:	Affected: 1	Dead: 1
Owner: Department of Conservation	Prev. Accn.:	Type: Post Mortem	

HISTORY

Found dead on Tiritiri Matangi Island on 12/12/2015. "Old female laying a clutch of eggs. When opened up body cavity was full of gunky egg-like material.

GROSS FINDINGS

Small tissue samples sent in 10% formalin.

HISTOPATHOLOGY

Lung: there is marked congestion.

Heart: the majority of cardiomyocytes contain small amounts of granular golden perinuclear pigment, likely lipofuscin or haemosiderin.

Liver: the majority of hepatocytes contain moderate amounts of granular golden intracytoplasmic pigment, likely lipofuscin or haemosiderin.

Intestine: the serosa of several loops of intestine are coated in small amounts of yolk material admixed with moderate numbers of medium-length, rod-shaped bacteria.

Sections of kidney show no obvious abnormalities.

DIAGNOSIS

Yolk and bacterial coelomitis

COMMENTS

Loops of intestine were coated in yolk material as well as colonies of bacteria. It seems likely the bird had an egg impaction which has enabled bacteria to ascend the oviduct. Some of the impacted egg material (and bacteria) has then refluxed back into the coelomic cavity.

Older female birds can become depleted of calcium body reserves after a lifetime of producing eggs.

Calcium is essential for proper contraction of the oviduct to push the eggs through the reproductive tract during egg-laying. Inadequate levels of calcium can sometimes result in retention of eggs within the oviduct leading to an egg impaction.

Institute of Veterinary, Animal and Biomedical Sciences
PATHOLOGY REPORT

Submitter's Ref.:	Date Sent: 08/01/2016	Accession No.: 52845
-------------------	-----------------------	-----------------------------

TO: Mhairi McCready
Department of Conservation
Tiritiri Matangi

Species: Avian-WL (1)	Sex: Female	Age: 5 Years	Breed: Hihi (Stitchbird)
ID: Leg band: C89967 Microc	At Risk:	Affected: 1	Dead: 1
Owner: Department of Conservation		Prev. Accn.:	Type: Post Mortem

HISTORY

Found dead in a nest box not belonging to this female. 2 dead chicks found alongside. Suspect fight/aggression but no obvious external signs of injury.

GROSS FINDINGS

The bird weighed 20.1 grams and was in moderate body condition; good pectoral muscle mass and adequate intra-abdominal fat stores.

The carcass was in moderate state of decomposition and had maggots within the coelomic cavity and colon.

No external signs of trauma (wounds, bleeding, feather loss) were identified on gross post-mortem.

Due to the state of decomposition, no other abnormalities were identifiable on gross post-mortem.

HISTOPATHOLOGY

Within the lungs, heart, kidney and adrenal gland, small numbers of small caliber blood vessels contain short, rod-shaped bacteria; there is no associated inflammatory reaction.

Liver: there are large numbers of lymphocytes with fewer plasma cells (and the rare Mott cell) expanded portal tracts and centrilobular areas; there is occasional lymphofollicular formation. The majority of hepatocytes contain small to moderate amounts of intracytoplasmic, granular yellow pigment, likely iron in the form of haemosiderin. Numerous colonies of short, rod-shaped bacteria are visible within and distending sinusoids; there is minimal associated inflammation.

Gizzard: three cross sections through adult nematodes are visible at the glandular-coilin junction.

Intestine: a single cestode is present within the lumen of one section of small intestine.

Sections of ovary and brain show no obvious abnormalities.

DIAGNOSIS

Uncertain cause of death; likely terminal bacterial septicaemia

COMMENTS

This bird was in good body condition with no observed signs of trauma on gross examination.

Histology of the internal organs show fairly large numbers of bacteria within the blood vessels of multiple internal organs. There was very little, if any inflammation associated with the bacteria, so it is likely the bacterial infection has occurred very quickly.

Intraspecific and interspecific aggression can be very stressful to a bird and may result in compromise of the bird's immune system which can make them more susceptible to bacterial infections. The likely source of the bacteria is from the bird's own intestine and it is unlikely this bird posed a risk in terms of other in-contact birds.

Institute of Veterinary, Animal and Biomedical Sciences

PATHOLOGY REPORT

Submitter's Ref.:	Date Sent: 29/01/2016	Accession No.: 52891
-------------------	-----------------------	----------------------

TO: Mhairi McCready
Department of Conservation
Auckland

Species: Avian-WL (1)	Sex: Male	Age: ~ 7 Years	Breed: Hihi (Stitchbird)
ID: C-86513	At Risk:	Affected: 1	Dead: 1
Owner: Department of Conservation	Prev. Accn.:	Type: Post Mortem	

HISTORY

Had been looking in poor condition for ~2 weeks, losing feathers around the eyes and beak, losing his voice, his call was sounding strange.

GROSS FINDINGS

The bird weighed 27 grams and was in poor body condition. There was patchy feather loss over the top of the head and around both eyes.

The syrinx/tracheal bifurcation and the base of the heart were obscured by firmly adherent yellow caseous material.

No other abnormalities were noted on gross post mortem.

HISTOPATHOLOGY

Lung: there is marked congestion.

Interclavicular airsac: the epithelium is absent and is replaced by a large core of eosinophilic debris admixed with numerous fungal elements bordered by a thick layer of necrotic inflammatory cells also admixed with large numbers of fungal elements. There is transmural necrosis of a large artery in which the wall is also thickened due to infiltration with necrotic inflammatory cells admixed with pyknotic debris and large numbers of fungal elements.

Liver: the majority of hepatocytes contain small amounts of granular, golden intracytoplasmic pigment, likely iron in the form of haemosiderin and/or lipofuscin.

Gizzard: five cross sections of adult nematodes are present at the glandular-koilin level; there is no associated inflammatory response.

Sections of skeletal muscle, heart, kidney, proventriculus, intestine and testis show no obvious abnormalities.

DIAGNOSIS

Mycotic airsacculitis (Aspergillosis)

COMMENTS

Cheesy yellow material was present over the voicebox and parts of the interclavicular airsac of this bird; this is most consistent with an infection with the fungus *Aspergillus*, which was confirmed on histological exam. Several roundworms (nematodes) were present in the lining of the gizzard; there was no associated inflammatory reaction and it is likely these are an incidental finding.

The feather loss around the eyes is possibly due to mites but we did not see any on feather/skin scraping.

Institute of Veterinary, Animal and Biomedical Sciences

PATHOLOGY REPORT

Submitter's Ref.:	Date Sent: 17/03/2016	Accession No.: 53088
-------------------	-----------------------	----------------------

TO: Victoria Franks and Mhairi McCreedy
Department of Conservation
Tiritiri Matangi

Species: Avian-WL (1)	Sex: Male	Age: Adult	Breed: Hihi (Stitchbird)
ID: CP-2844	At Risk:	Affected: 1	Dead: 1
Owner: Department of Conservation	Prev. Accn.:	Type: Post Mortem	

HISTORY

Found in supplementary feeder 14th March perky but unable to use legs. Due to be sent for vet consultation but died a morning of 16th March.

GROSS FINDINGS

The bird weighed 27.7 grams and was in poor to moderate body condition. The mandibles were not fused, with the tip of the right mandible deviated laterally and the left mandible straight but shortened; there was a skin/soft tissue between the mandibles.

The cloaca was moderately distended with gas and urates.

There was marked atrophy of the muscles of the right leg. Just to the right of the midline of the synsacrum (near the level of the hip joints) was a ~8mm area of yellow mottling to the bone of the synsacrum.

No other abnormalities were noted on gross post mortem.

HISTOPATHOLOGY

Synsacrum and associated soft tissues: there is a mass effect resulting in destruction of the lateral aspect of the vertebral cortical bone, replacement of the hypaxial and epaxial musculature as well as compression of the spinal cord and dorsal aspect of the kidney. The mass effect is due to multiple irregular cores of densely eosinophilic amorphous debris admixed with large numbers of fungal elements. These cores are lined by a variably thick layer of epithelioid macrophages, multinucleated giant cells and heterophils with an outer layer of loose oedematous and congested fibrous tissue infiltrated with small numbers of lymphocytes and plasma cells. As well as compression of the spinal cord there is congestion and multifocal necrosis and heterophilic infiltration; fungal elements are present in these foci.

DIAGNOSIS

Mycotic (fungal) osteomyelitis, myositis and myelitis

Congenital deformity of the lower jaw

COMMENTS

This bird has a fungal infection in the bone of the synsacrum (osteomyelitis). The infection has destroyed the bone and is spreading into the spinal cord (myelitis) and adjacent skeletal muscle (myositis). The inflammation and damage to the spinal cord and surrounding nerves would explain why the bird could not use his legs.

No similar lesions were noted in the internal organs. The source of the infection could either be via the bloodstream or possibly from a previous wound to that area.